

Photochemical Tissue Bonding: Photons for Healing

Robert W. Redmond^{*a}, Irene E. Kochevar^a, Christopher Amann^a, Barbara P. Chan^a,
William A. Farinelli^a, R. Rox Anderson^a, Dimitri T. Azar^b, T. Shane Johnson^c,
J. Winograd^c and Mark A. Randolph^c

^a Wellman Center for Photomedicine, Harvard Medical School, Massachusetts General Hospital,
Boston MA 02114

^b Cornea and Refractive Services, Harvard Medical School, Massachusetts Eye and Ear Infirmary,
Boston, MA 02114, USA

^c Plastic Surgery Research Center, Department of Surgery, Massachusetts General Hospital,
Boston, MA 02114

Redmond@helix.mgh.harvard.edu

ABSTRACT

Tissue adhesion can be achieved using lasers in a non-thermal process called photochemical tissue bonding (PTB) as well as by the better known processes in which the tissue is heated to achieve welding or soldering. In PTB the energy of the absorbed photons is used to drive photochemical reactions via activated chemical species. Covalent bonds (“nanosutures”) formed between protein molecules bind the tissue surfaces together. In our PTB approach the photosensitizer used superficially stains the tissue such that effects are limited to the tissue interface. The overall temperature rise and concomitant thermal damage is negligible and structural integrity of the tissue is retained. This technology is generally applicable, but not limited to, collagenous tissues. In recent years we have used PTB for corneal repair, skin incision repair and skin grafts, tendon repair, nerve repair and blood vessel repair. In most cases, in vitro results have been followed by promising in vivo studies in appropriate animal models. Immediate repair strength, long term wound healing and functional recovery are all important factors governing the applicability of PTB in any given tissue and have been a focus of our work. This contribution will summarize our experience in mechanisms behind PTB, factors that influence the efficacy of PTB in various tissues and a comparison to other modalities for tissue adhesion and repair.

1.0 INTRODUCTION

Tissue repair is an obvious requirement following traumatic injury or surgical procedures. For most situations the tried and tested methods of mechanical methodologies, such as sutures, clips and staples, provide a cheap, rapid and efficient means of repair. However, in some situations these approaches are not particularly appropriate. Disadvantages include the placement of a foreign body in the tissue with resultant potential for inflammation and scarring. It is also generally true that the larger the structure to be repaired the easier the use of sutures. The opposite applies in that suture placement in microsurgery is technically more difficult. There are also a number of tissues that do not lend themselves easily to mechanical repair. Cornea is a particular example where suture repair is not optimal for a variety of reasons.[1] Microsurgery in blood vessel and nerve repair is also difficult due to the necessity of tightly sealing off the tissue environment.[2] Thus, there is a possibility that a suitable, less invasive technology for tissue repair will be of value for specific applications.

Paper presented at the RTO HFM Symposium on “Combat Casualty Care in Ground Based Tactical Situations: Trauma Technology and Emergency Medical Procedures”, held in St. Pete Beach, USA, 16-18 August 2004, and published in RTO-MP-HFM-109.

Laser energy has been used in a number of approaches for tissue repair. Lasers have been used in welding tissues together via a photothermal mechanism, involving conversion of the absorbed light energy to heat and subsequent protein denaturation and modification, resulting in bonding of the tissue.[3] As a thermal mechanism operates there is a high requirement for control of laser parameters such that welding is confined as much as possible to the tissue interface and does not contribute to collateral thermal damage in the tissue, which can cause excessive scarring and loss of structural integrity. [3-5] A means to more readily localize the thermal effects involves the application of a dye to the tissue surfaces that specifically absorbs the laser light; thus, thermal relaxation produces only highly localized temperature increase.[6, 7] Further adaptations of laser thermal welding involve the use of solders (protein or other macromolecules) to increase the bonding effect, but the mechanism is still activated in a thermal manner.[3, 8-10]

The use of lasers to activate tissue repair can be also be carried out through chemical, rather than thermal processes.[1, 11] In photochemical tissue bonding (PTB) the light energy activates a photosensitizing dye to produce chemical reactions that result in chemical bonding and subsequent tissue repair. PTB has inherent advantages over thermal mechanisms in that the process does not require tight control of dosimetry because a particular target temperature is not required and by avoiding the higher temperatures involved in laser thermal welding, denaturation can be avoided and structural organization of the tissue could be retained. With the law of reciprocity in photochemistry one is required only to provide a given light and dye dose to achieve the desired effect. As the PTB process is not dependent on thermal effects, the light dose can be delivered in an irradiance independent fashion. However, the irradiance is not without limits since there will generally be some element of heat release, even in an efficient photochemical system. Consequently, a very high irradiance can lead to thermal damage as a side effect.

This paper presents some of our recent experience with PTB in our laboratory, the mechanism by which PTB operates and practical issues that arise in its application to tissue repair and wound closure in different tissues.

2.0 METHODOLOGY

In its simplest conception PTB consists of application of a photoactive dye to the tissue surfaces, followed by intimate approximation of the tissue and illumination of the interface with visible light. The photoactive dye absorbs strongly at the wavelength of the illuminating light and the selective absorption essentially limits the photochemistry to the interface. One corollary is that the dye itself remains superficially bound to the tissue and does not penetrate to a great extent from the surface of the tissue.[12]

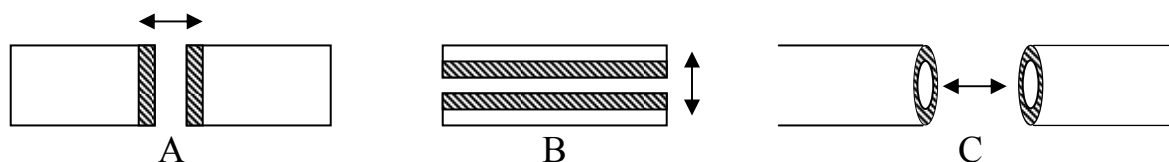


Figure 1: end to end (A), sandwich (B) and circumferential (C) approximation.

In our studies we have used rose bengal (RB), a dye that absorbs in the visible spectrum that has other clinical uses[13], in combination with green light from Argon ion (514 nm) or CW Nd/YAG (532 nm) lasers. RB was applied in all cases as a 0.1% (w/v) solution in aqueous phosphate buffer. Irradiation has been applied as a circular spot, a line of 2 mm diameter and an annulus through the use of a computer-driven scanning device. The beam geometry was chosen for the specific application. The irradiance (W/cm^2) of the light was varied in some cases using filters and the fluence (J/cm^2) was varied by changing the period of illumination.

3.0 RESULTS

3.1 Corneal Repair

Primary feasibility studies were carried out on cornea.[1] The cornea is particularly attractive for PTB as it is transparent, avascular and largely acellular except for the surface layers and it is comprised predominantly of collagen. Cornea is also not ideal for suture placement as it is the primary refractive component of the eye and uneven suture tension can lead to post-operative astigmatism. In preliminary studies to test the ability of PTB to create an immediate bond in corneal tissue, a full thickness incision was created through the cornea of enucleated rabbit eyes (New Zealand white rabbit) with a 3.5 mm beveled keratome. Rose Bengal dye (20 μ l of a 0.1% w/v solution) was applied to the walls of the incision via syringe and the wound was then irradiated with 514 nm light from an argon ion laser under different conditions of fluence and irradiance. Strength of repair was measured by controlled injection of saline into the anterior chamber and measurement of the increase in intraocular pressure (IOP) using a pressure transducer until a pressure was reached where the sealed incision was ruptured and leakage occurred (IOP_L). Figure 2 shows the IOP_L levels measured following repair of corneal incisions as a function of the light fluence used when delivered at a constant irradiance of 0.8 W/cm². An increased repair strength was observed up to a total fluence of 800 J/cm². The reduction seen at fluences higher than 800 J/cm² may indicate thermal damage under these conditions when no cooling was applied to the tissue.

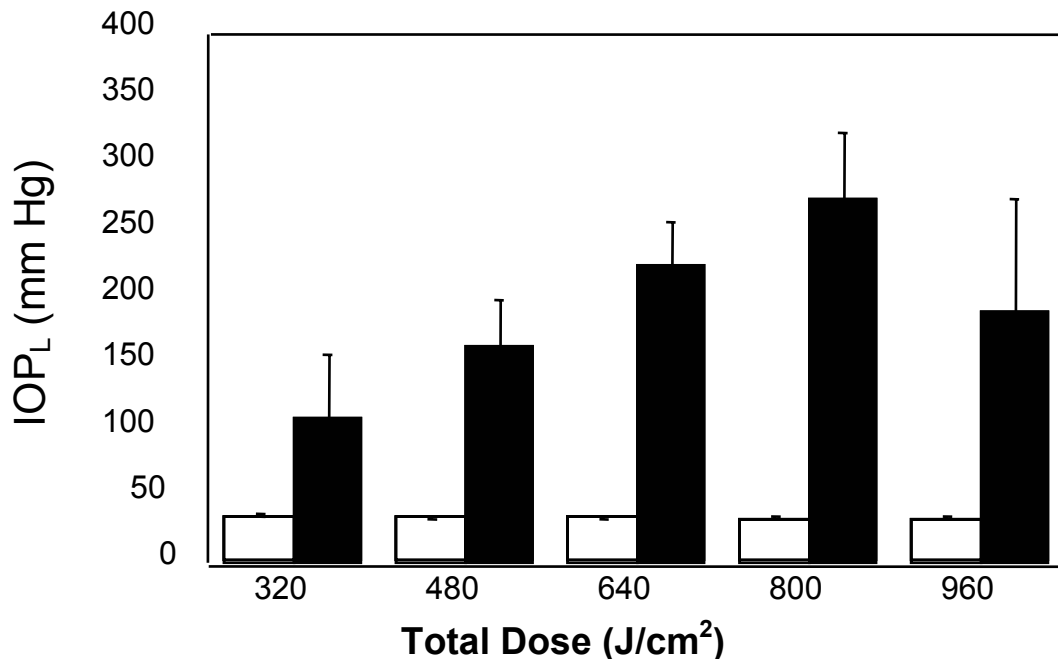


Figure 2: Fluence dependence of strength of repair of corneal incision as a function of total fluence delivered at an irradiance of 0.8 W/cm².

Figure 3 shows the results obtained for the same fluence range but delivered at a 3x higher irradiance. Comparison of figures 2 and 3 shows that the use of increased irradiance in an attempt to deliver the required light fluence as quickly as possible was not successful as the resulting repair strengths were lower. In addition to the reduced efficacy of repair, the cornea underwent shrinkage, indicative of thermal overload to the tissue. This highlights a major consideration in PTB in that there is a balance required between fluence and irradiance

and that use of high irradiances can be detrimental to the outcome. However, cooling can be employed to minimize the thermal effect and allow for use of higher irradiance

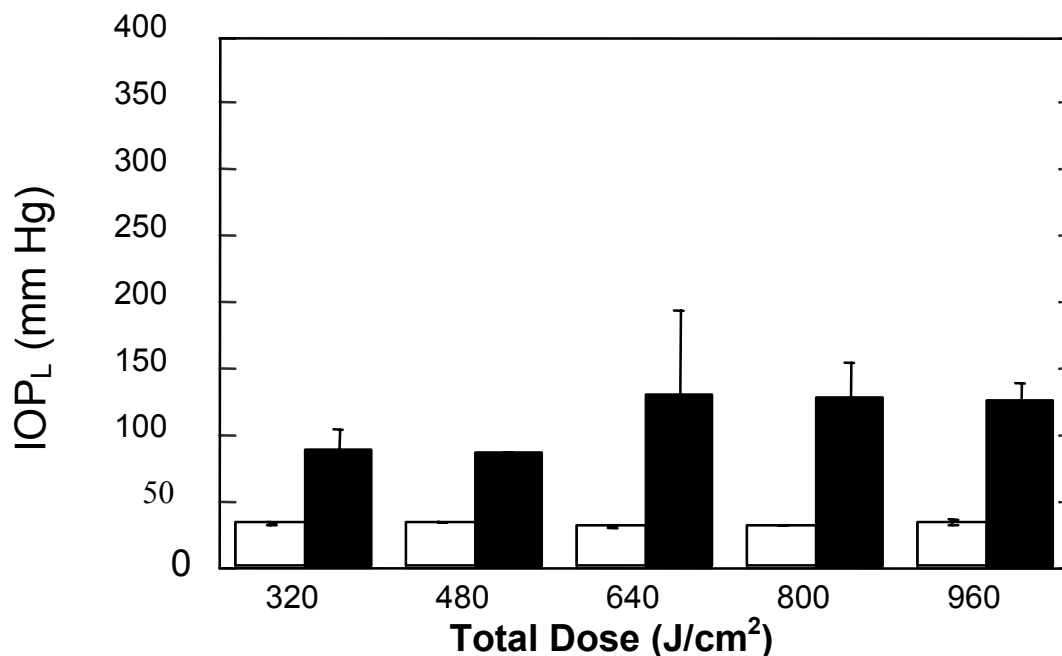


Figure 3: Fluence dependence of strength of repair of corneal incision as a function of total fluence delivered at an irradiance of 2.4 W/cm².

These preliminary experiments prompted in vivo tests in the same rabbit model, using the same incision wound. Following repair the intraocular pressure required to rupture the repair was determined by injection of saline into the anterior chamber. The results were more impressive in vivo because the same repair strength required an order of magnitude less fluence (~ 40 J/cm²); consequently, the irradiation time was reduced to a few minutes. We have found this to be fairly typical in our experiments to date in different tissues. In addition to measurements of immediate repair strength, the time dependence of repair strength and wound healing responses were followed up to four weeks post-treatment. There was no reduction in wound repair strength in the days following treatment, in fact greater strength was observed as healing progressed. There were signs of neovascularization after two weeks but this resolved after four weeks and was initiated by the incision itself rather than the treatment. Thus, the use of PTB corneal surgery has promise.

A further test of PTB for corneal applications was carried out in penetrating keratoplasty (PK, corneal graft). This is a particularly good problem for the PTB approach as the use of sutures to secure a corneal graft is problematic due to the slow healing process in the cornea that requires the sutures to remain in place for a considerable time, thus increasing the possibilities of adverse reaction due to foreign body response and ultimate graft rejection. The placement of sutures also introduces post-treatment astigmatism due to uneven suture tension that requires follow-up outpatient visits for adjustments to be performed. Experimentally, a 7 mm circular graft was harvested from one eye using a trephine. Rose Bengal solution was then applied to the cut surface of the host tissue and to the outer circumference of the graft and the corneal “plug” was then replaced in the host and held in place with 4-8 stay sutures. Irradiation was performed using a CW Nd/YAG laser at 532 nm with the 2 mm diameter spot being scanned to describe a circle of 7 mm diameter. In this

fashion the light was limited to the interface between graft and host with a small border of overlap. Following illumination the intraocular pressure to cause leakage from the sealed graft was measured in the same manner as for incisional wounds. The contralateral eye was treated in similar fashion except that the stay sutures alone were placed without PTB treatment. In all cases the pressure to cause leakage from the graft/host interface was higher when PTB was used to seal the interface. One obvious but important success factor to come out of this work was the need for intimate contact between the tissue surfaces to be bonded. As PTB works through formation of covalent bonds, bonding occurs on a molecular scale and the surfaces must be in tight, intimate contact. In grafts where we did not have good approximation at certain sites in the circumferential interface the seal was incomplete and leakage occurred at lower intraocular pressure. It should also be noted that the IOP to cause leakage from the interface is higher in control eyes for transplants compared to incisional wounds as the sutures do provide a seal, albeit incomplete, that reduces leakage at lower pressures.

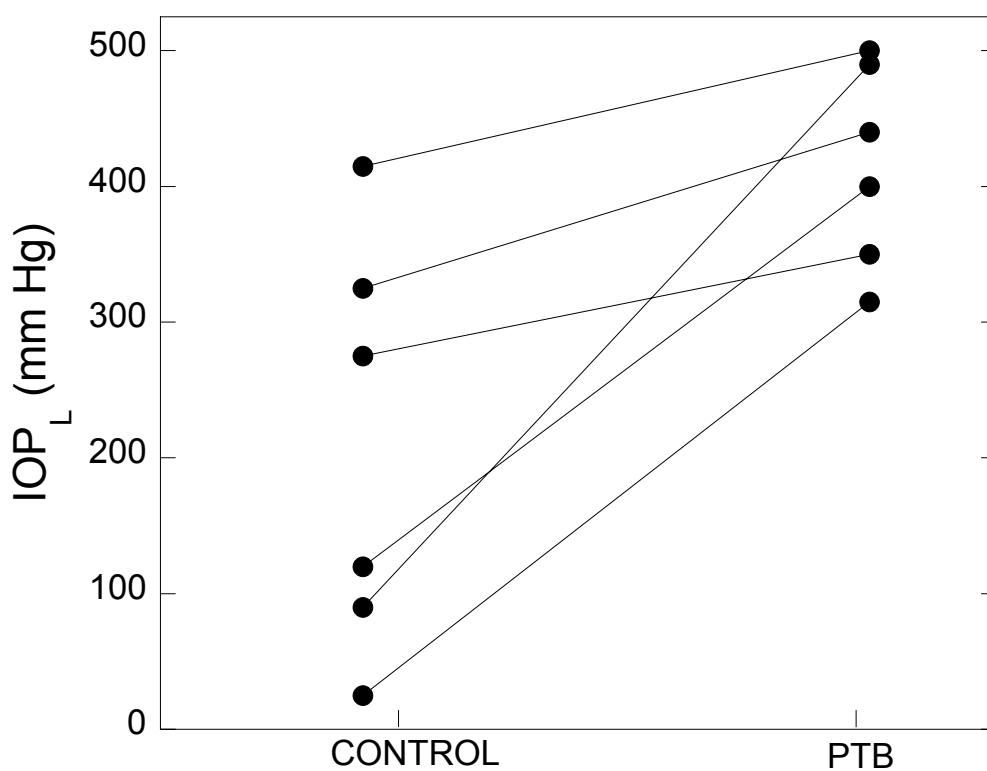


Figure 4: Increase in IOP_L from control (stay sutures only) to PTB-treated corneal transplants in New Zealand white rabbits.

3.2 Peripheral Nerve Repair

As shown in Fig. 1 there are a number of ways in which tissues can be bonded using PTB. In the corneal examples given above the bonding is of the end to end type (A). For cylindrical structures like nerve or blood vessels PTB is applied to the outer periphery only. Peripheral nerve fibers are enveloped by a sheath of connective tissue called the epineurium. Nerve repair is done at the level of tissue repair rather than cellular repair, with the simplest approach being reconnection at the epineurium, which then protects the environment of the nerve interior to allow healing to occur.[2, 14] When a severed nerve is placed in a solution of rose bengal the dye is taken up exclusively by the collagenous epineurium. The endoneurium and nerve fibers are

not stained. This is ideal for peripheral nerve repair as an epineurial seal can be created using PTB. The approach we have used is shown in Figure 5 where an epineurial cuff is created as shown, to increase the surface area between the approximated tissue surfaces.

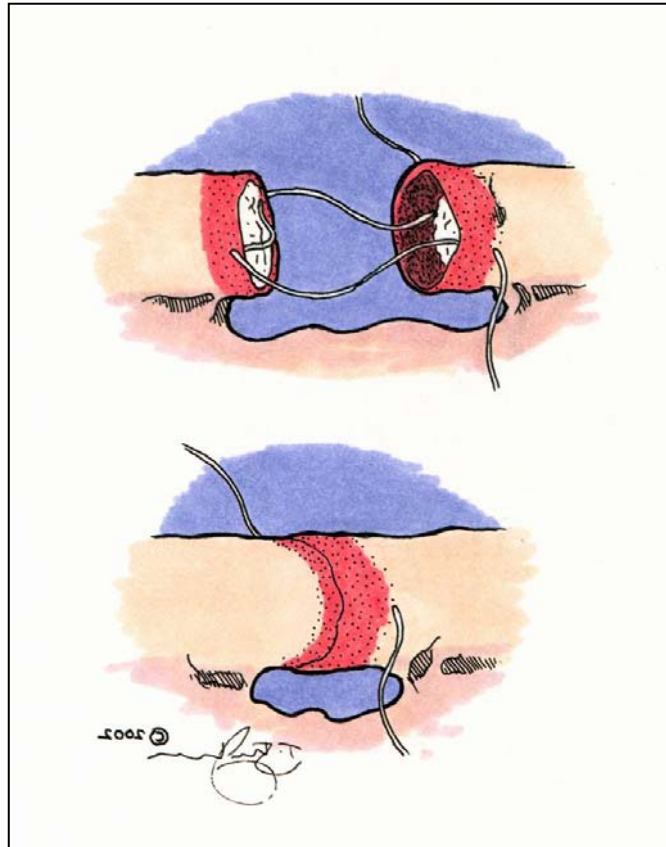


Figure 5: Cartoon showing epineurial cuff approach to peripheral nerve repair using PTB.

We have used this approach to test the feasibility of PTB for peripheral nerve repair in a rat model. The sciatic nerve was isolated and transected in Sprague-Dawley rats and the following treatments were performed. Ten animals were used for each treatment group.

1. Microsuture repair (current standard of care).
2. No repair (proximal nerve stump was sutured into muscle to prevent any possibility of regrowth).
3. Epineurial cuff alone.
4. Epineurial cuff + PTB using RB and 532 nm light ($0.5\text{W}/\text{cm}^2$, 2.5 minute exposure).

Figure 6 shows a photograph of a rat sciatic nerve that was transected and then repaired using the epineurial cuff and PTB approach. The photo on the left shows a rat sciatic nerve immediately following the PTB treatment and the cuff is clearly visible. The photograph on the right was taken 90 days after treatment and shows the repaired nerve that is free from any signs of external scarring or gross inflammation. The suture in this picture was placed to aid the histologist in locating the repair site.

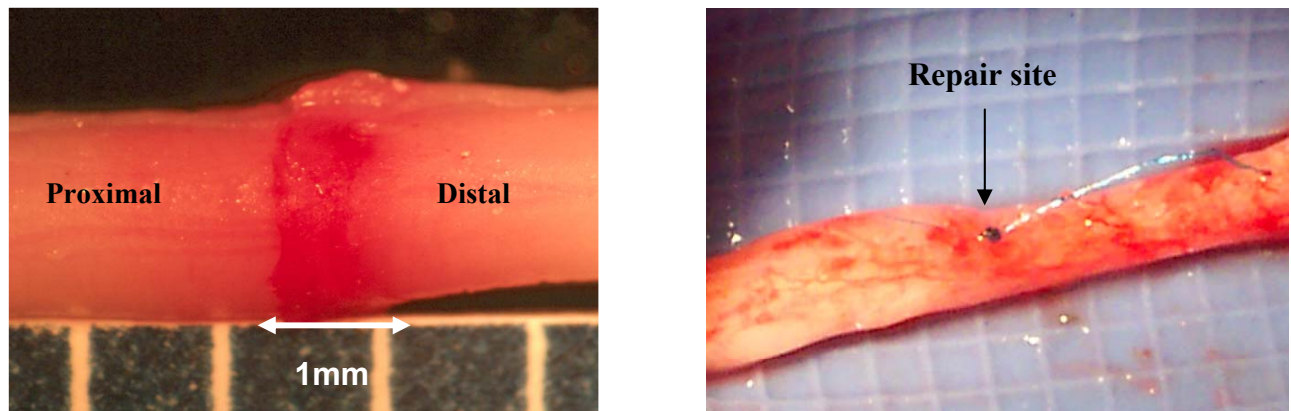


Figure 6: Left Panel – rat sciatic nerve immediately following repair using epineurial cuff + PTB approach. Right Panel – rat sciatic nerve 90 days after repair using epineurial cuff + PTB approach.

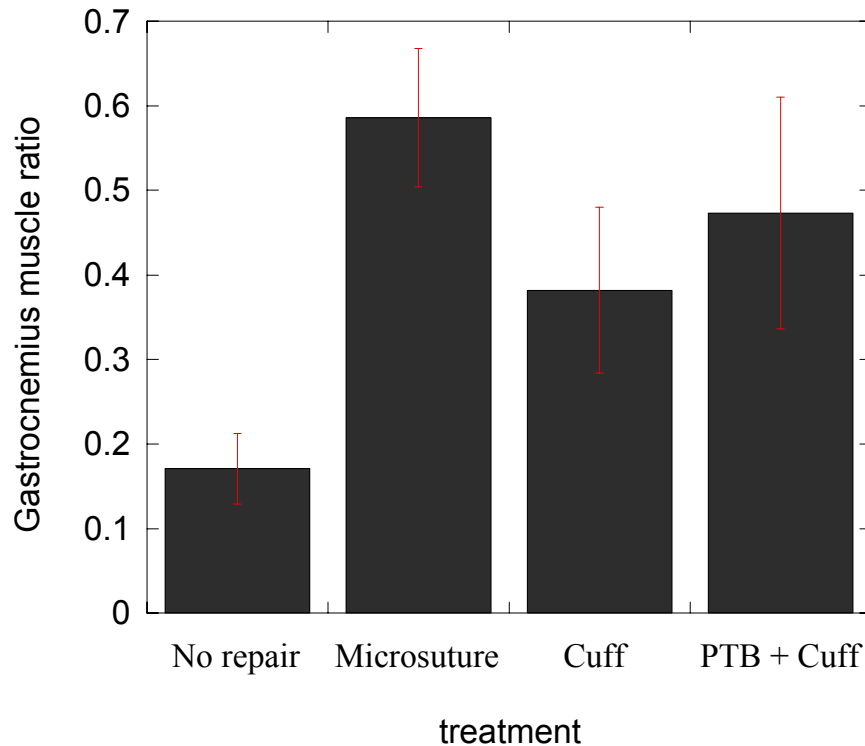


Figure 7: Ratio of gastrocnemius muscle weight in treated versus untreated hind limbs of rats at 90 days following transection of the sciatic nerve as a function of repair treatment used.

The end-points studied included retention of gastrocnemius muscle (enervated by the sciatic nerve) and histology for regrowth of myelinated axons in the distal stump. In the former the muscle weight in the treated limb was compared to the weight of the same muscle in the untreated hind limb. At the 90-day end point the muscles were harvested and the ratio of the muscle weights in treated and untreated limbs are presented as a function of treatment in Fig. 7. In the negative control where no regrowth was possible, the gastrocnemius muscle in the treated leg wasted away and a low ratio was obtained. Retention of muscle mass was obtained

with all other treatments. In the cuff alone group sutures were placed to form the cuff as shown in Figure 5. The cuff alone does not provide a strong seal but provides some benefit in terms of nerve repair. The additional bonding provided by the cuff + PTB approach enhanced the recovery as seen by a higher ratio of muscle weights in treated to untreated limbs approaching the best results obtained using standard of care microsurgery where 6 epineurial microsutures were placed at the repair site. A possible reason for the slightly lower effects seen with PTB is that in formation of the cuff the nerve length is reduced by 1-2 mm, which imparts an increased tension on the nerve, a factor that is known to be detrimental to nerve regrowth. Thus, although PTB seals the nerve environment to allow healing the cuff approach does impart some negative side effect. This could be overcome using a graft approach where the length of the nerve is not reduced overall.

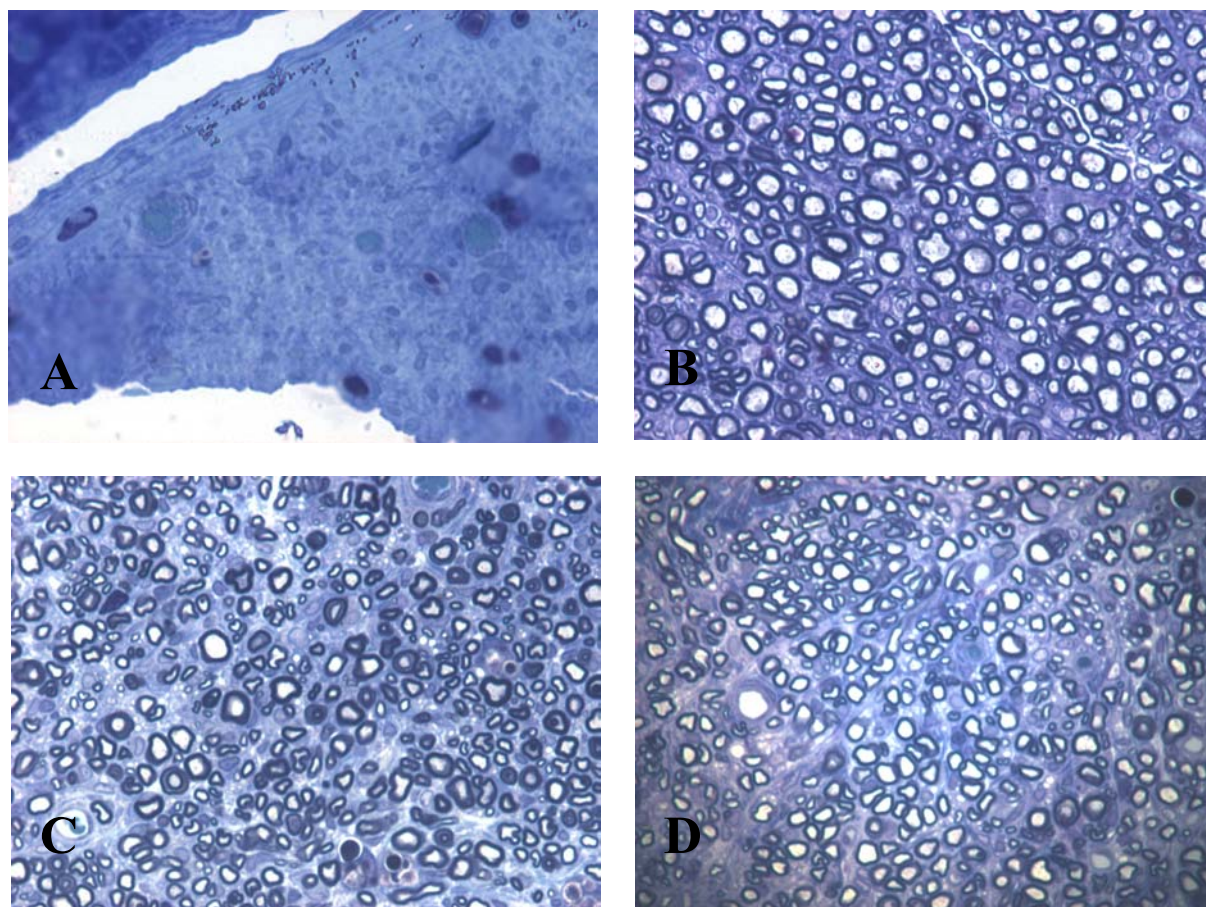


Figure 8: Histological sections (400x) of nerve harvested at 90 days post-treatment and stained for regrowth of myelinated axons using toluidine blue. A. No repair, distal to repair site. B. PTB + cuff, at repair site. C. PTB + cuff, proximal to repair. D. PTB + cuff, distal to repair.

The best analysis of regrowth following peripheral nerve repair is provided by histology of the repaired nerve by comparison of sections taken at the repair site and at points proximal and distal to the site. The presence of myelinated fibers distal to the repair site is indicative of nerve regrowth. Sections were stained with toluidine blue to detect regenerated myelinated fibers. Figure 8 shows histological sections obtained at different sites following different treatments. In all cases, the section taken proximal to the nerve shows myelinated axons as expected as the deterioration of the nerve occurs distal to the site of injury. Thus, comparison of proximal and distal sections allows analysis of extent of nerve regrowth. In the negative control (A) where no repair

was carried out there is a complete absence of myelinated fibers in the nerve distal to the repair site. Sections C and D show sections from nerve repaired using the PTB + cuff approach at sites proximal and distal to the repair site, respectively. It is clear from section D that a large amount of the axons have regenerated into the distal stump. Section B shows a section through the repair site itself and is notable for a lack of scarring or otherwise irregular histology at the repair site itself. This is an important finding as microsutures can cause significant scarring, which is known to be detrimental to regrowth and functional recovery.[14] In conclusion, PTB used in this fashion has potential for microsurgical applications where sutures can be problematic.

3.3 Blood Vessel Anastomosis

Another example of a circumferential bond is in reanastomosis of severed blood vessels. This area was studied in detail in laser welding research in the past and is also highly appropriate for PTB.[3, 4, 15, 16] We have carried out preliminary studies using pig blood vessels ex-vivo in conjunction with PTB using rose bengal and a CW Nd/YAG laser. We have again used the cuff approach to increase the surface area of overlap to provide for a strong seal.

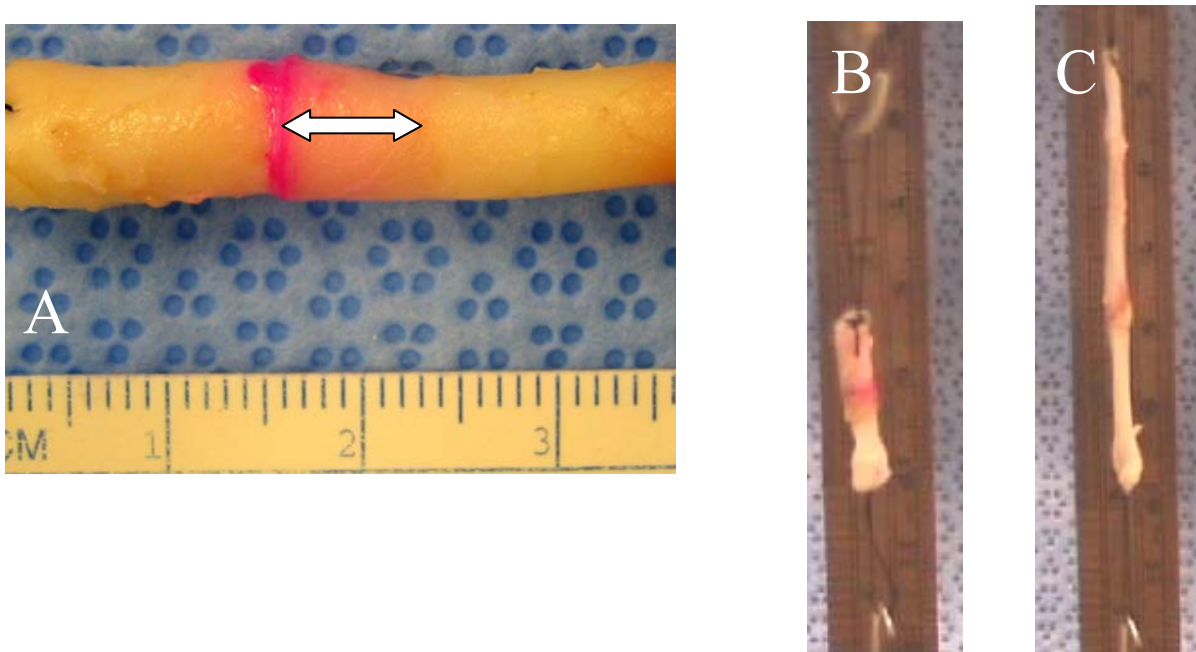


Figure 9: A. Swine carotid artery showing overlap of proximal and distal ends in cuff (arrow). B. Repaired pig vein on tensiometer before measurement. C. Stretching of vein to 3 times its normal length without rupture of repair.

Figure 9A shows the overlap area in a cuff created in the repair of a severed pig carotid artery ex vivo. The red color of the rose bengal is visible prior to irradiation. For blood vessel anastomosis we have used 532 nm irradiation parameters of 1.5 W cm^{-2} for 2.5 minutes (450 J/cm^2) on each side of the vessel. Figure 9B shows a repaired pig vein mounted on a tensiometer prior to measurement of tensile strength. Figure 9C demonstrates the strength of the repair as the vein stretches to 3-4 times its normal length and resists a force of $\sim 2\text{ N}$ before the seal is ruptured. These encouraging preliminary results have now led to in vivo studies of anastomosis in the rat femoral artery model where a complete seal is observed following PTB and circulation can be re-established without leakage of blood. Experiments are currently underway to look at longer term effects following PTB repair in blood vessels.

4.0 CONCLUSIONS

Photochemical tissue bonding (PTB) has proven to have potential in the repair of a variety of different tissues, especially those rich in collagen. The examples shown here demonstrate the different types of joints or seals that can be achieved. In addition to these examples of cornea, nerve and blood vessel PTB has also been successfully applied to repair wounds in skin, tendon and larynx. Many other possibilities exist and PTB has potential for being a platform technology that could be widely applied in surgical settings. The important factors for successful PTB include a strong adsorption of the photoactive dye to the target tissues, a minimization of thermal effects through correct dosimetry and external cooling and an intimate approximation of the tissue surfaces such that covalent crosslinks or “nanosutures” can be formed at the interface. PTB is particularly appropriate for small or delicate structures where placement of conventional sutures is physically difficult, time-consuming or liable to cause unwanted side effects.

5.0 ACKNOWLEDGEMENTS

The authors are grateful for funding from the Medical Free Electron Program (MFEL) of the Department of Defense, from the Center for the Integration of Medicine and Innovative Technology (CIMIT) and for Research Fellowships on Laser Medicine from the Department of Energy.

6.0 REFERENCES

- [1] Mulroy, L.; Kim, J.; Wu, I.; Sharper, P.; Melki, S. A.; Azar, D. T.; Redmond, R. W.; Kochevar, I. E., Photochemical keratodesmos (PKD) for repair of lamellar corneal incisions. *IOVS* **2000**, 41, 3335-3340.
- [2] Hall, S., Nerve repair: a neurobiologist's view. *J Hand Surg (Br)* **2001**, 26, (2), 129-136.
- [3] Bass, L. S.; Treat, M. R., Laser tissue welding: A comprehensive review of current and future clinical applications. *Lasers Surg Med* **1995**, 17, 315-349.
- [4] Guo, J.; Chao, Y. D., Low power CO2 laser assisted microvascular anastomosis: an experimental study. *Neurosurg* **1988**, 22, 540-543.
- [5] Naseef, G. S.; Foster, T. E.; Trauner, K.; Solhpour, S.; Anderson, R. R.; Zarins, B., The thermal properties of bovine joint capsule. The basic science of laser and radiofrequency-induced capsular shrinkage. *Am J Sports Med* **1997**, 25, (5), 670-674.
- [6] DeCoste, S. D.; Farinelli, W.; Flotte, T.; Anderson, R. R., Dye-enhanced laser welding for skin closure. *Lasers Surg Med* **1992**, 12, (1), 25-32.
- [7] Chuck, R. S.; Oz, M. C.; Delohery, T. M.; Johnson, J. P.; Bass, L. S.; Nowygrod, R.; Treat, M. R., Dye enhanced laser tissue welding. *Laser Surg Med* **1989**, 9, 471-.
- [8] Maitz, P. K.; Trickett, R. I.; Dekker, P.; Tos, P.; Dawes, J. M.; Piper, J. A.; Lanzetta, M.; Owen, E. R., Sutureless microvascular anastomeres by a biodegradable laser-activated solid protein solder. *Plast Reconstr Surg* **1999**, 104, (6), 1726-1731.

- [9] McNally, K. M.; Sorg, B. S.; Welch, A. J., Novel solid protein designs for laser assisted tissue repair. *Lasers Surg Med* **2000**, 27, (2), 147-157.
- [10] Hodges, D. E.; McNally, K. M.; Welch, A. J., Surgical adhesives for laser assisted wound closure. *J Biomed Opt* **2001**, 6, (4), 427-431.
- [11] Judy, M. M.; Matthews, J. L.; Boriack, R. L.; Burlacu, A.; Lewis, D. E.; Utecht, R. E., Photochemical cross-linking of proteins with visible light absorbing 1,8-naphthalimides. *Proc. SPIE* **1993**, 1882, 221-224.
- [12] Chan, B. P.; Kochevar, I. E.; Redmond, R. W., Enhancement of porcine skin graft adherence using a light-activated process. *J Surg Res* **2002**, 108, (1), 77-84.
- [13] Lansche, R. K., Vital staining in normal eyes and in keratoconjunctivitis sicca. *Am J Ophthalmol* **1965**, 60, 520-525.
- [14] Lee, S. K.; Wolfe, S. W., Peripheral nerve injury and repair. *J Am Acad Orthop Surg* **2000**, 8, (4), 243-252.
- [15] Zeebregts, C. J.; Heijmen, R. H.; vandenDungen, J. J.; van Schilfgaarde, R., Non-suture methods of vascular anastomosis. *Brit J Surg* **2003**, 90, 261-271.
- [16] Werker, P. M.; Kon, M., Review of facilitated approaches to vascular anastomosis surgery. *Annals of Thoracic Surgery* **1997**, 63, (S122-127).

